

## Effects Aerosol of Industrial Bleach and Detergent Mixture on Mucosa Layer and Lamina Mucosa Conjunctiva in Mice

Gh. Vaezi<sup>1</sup> \*, M. Pourkazem<sup>2</sup>, F. Toosi<sup>2</sup>, F. Aliabadi<sup>2</sup>

<sup>1</sup> Associate professor, Damghan Branch, Islamic Azad University, Damghan , Iran

<sup>2</sup>Department of Biology, Faculty of Science, Damghan Branch, Islamic Azad University, Damghan , Iran

(Received: 20 January 2013

Accepted: 10 February 2013)

**Abstract:** Today bleach and detergents are being frequently used and some people use their mixture for more cleaning. Because of chemical interaction of bleach and detergent, chlorine gas was released and thereby it could be dangerous for human health. This study examined the effects of exposed toxic mixture of bleach and detergent on the Mucosa layer and Lamina mucosa conjunctiva in the mice. In this study, 42 adult male mice NMRI race weighing 35-40 gr and from age 8 to 10 weeks were divided into 6 experimental groups and one control group. Experimental groups 1-2-3 with the use of chamber, the exposed 20 minutes were exposed to spray the amount 1 cc of mixture of bleach and detergent by nebulizer. Experimental groups 4-5-6 were for 35 minutes to inhale the same amount of material. Mice killed at 24-48-72 hours after exposed and the Mucosa Layer and Lamina mucosa conjunctiva tissue was studied pathology. In the study of microscopic sections prepared of mouse mucosa layer and Lamina mucosa conjunctiva tissue experimental group comparison with the control group, significant decrease was observed in mucosa layer the have ( $p \leq 0.001$ ) and significant decrease was observed in the Lamina mucosa have ( $p \leq 0.01$ ,  $p \leq 0.001$ ). As a result, increasing the exposed time of mixing bleach and detergent, as time passed, increasing the tissue damage and changes.

**Keywords:** bleach, detergents, chlorine, Mucosa layer, Lamina mucosa aerosol, mice.

### INTRODUCTION

Detergents can clean fat and dirt particles in various forms [9]. There are different types of bleach: chlorinated or household bleach containing sodium hypochlorite (NaClO) which is also called Javel water or vaytex. The bleach solution in water to form 5 or 10 percent will be offered. Vaytex is an oxidizer. Other types of non-chlorine bleach contain hydrogen peroxide or sodium perborate or sodium is percarbonate and finally the calcium hypochlorite is a bleaching powder [6]. People for more cleaning use of mixed bleach and detergents that lead to more release of chlorine gas and thereby increase the severity of the symptoms of poisoning [23]. Most cases of poisoning were caused by inhaling these compounds in the space

causing chlorine gas that could irritate the airways and can cause symptoms of poisoning individuals [7,16].

Chlorine was discovered by Scheele in 1774, at atmospheric pressure and room temperature. Elemental chlorine is a gas. It is yellowish-green and the characteristic smell of bleach. The combined chlorine bleach with detergent could cause more and more harmful effects [12].

The most important effects of chlorine gas in the body caused by free radicals of oxygen. Oxygen is an essential element of life can be severely harmful effects on the body, under certain conditions. Many of the harmful effects of oxygen due to the formation and activity of chemical compounds are known as reactive oxygen species

**Corresponding Author:** Gh. Vaezi, Associate professor, Damghan Branch, Islamic Azad University, Damghan , Iran. Email: gn.vaezi@yahoo.com

(ROS) [5].

Free radicals are the agent of many diseases and fatal cancers [14]. Oxygen free radicals are molecules that are generated in the reduction of molecular oxygen. These compounds are produced in cells from several directions. But most of the activities are performed in mitochondria, because mitochondria are the main places in which oxygen are reduced [9, 21] and cause damage in 4 points to the body, including lipid compounds, proteins, DNA and is the lysosome and thus can lead to cell damage and eventually cell death [15].

### MATERIALS AND METHODES

In this study of 42 adult male mice, NMRI race were used with weighing 35-40 gr, and age range from 8 to 10 weeks, they were purchased from Karaj Anistito Pastor. Animals were kept at 23- 25 °C temperature and light conditions under the standard 12 hours light and 12 hours of darkness and a relative humidity of 40 to 60 percent water and food. The animals were randomly divided into 6 experimental groups 1-2-3-4-5-6 and one control group. Test group 1-2-3 included 18 mice in the chamber dimensions were  $30 \times 30 \text{ cm}^3$  to 20 minutes. Value 0.5 cc of bleach and detergent material was poured into the nebulizer to spray and mice were exposed to it. Experimental groups 4-5-6 were for 35 minutes to inhale the same amount of material, Mice in groups of six were returned to cages and food and water were available to them.

Experimental groups 1-2-3 of mice were killed 24, 48 and 72 hours after inhalation respectively. Experimental groups 4, 5 and 6 were killed likewise and the mucosa layer and lamina mucosa conjunctiva tissue were pathologically studied. Bleach and detergent were obtained from kondor (ABC) Company.

*Preparation of tissue samples:* Samples after separation were in 10% formalin fixative solution for one week. After preparing the tissue by tissue processing system and molding samples using microtom system, 5-micron thick sections were cut. For histology studies, sections were stained with hematoxylin and eosin staining method.

### STATISTICAL ANALYSIS

The results were evaluated in the study between experimental and control groups considering mean and standard deviation (Mean  $\pm$  SEM). Statistical calculations were performed to evaluate significant differences between experimental and control groups using the test (ANOVA) followed by Turkey complementary test ( $P < 0.05$ ).

### RESULTS

The comparison thickness of Mucosa Layer in a dose of 1 cc, during exposed of 20 and 35 minutes showed that thickness this tissue has significantly decreased in all in experimental groups during (24, 48 and 72 hours) after exposed than control group (Fig1).

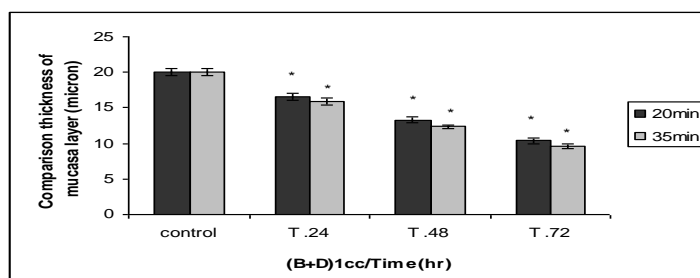


Figure 1: Comparison of mean  $\pm$  SEM thickness of mucosa layer conjunctiva tissue, 24-48-72 hours after exposed of a mixture of bleach and detergent, The amount of 1 cc, 20 and 35 minutes in duration Between experimental and control groups (\* $P < 0.001$  compared with control group) (n=6) (B+D  $\rightarrow$  Bleach + Detergent)

conjunctiva tissue in a dose of 1 cc, during

exposed of 20 and 35 minutes showed that thickness this tissue has significantly decreased in

3, 5 and 6 groups during 48 and 72 hours after exposed, than control group (Fig.2)

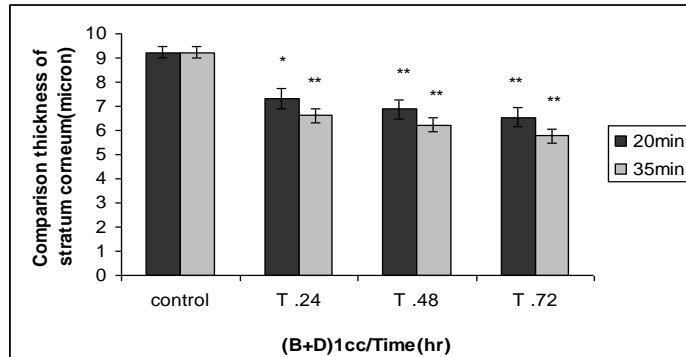


Figure 2: Comparison of mean  $\pm$  SEM thickness of Lamina mucosa conjunctiva tissue, 24-48-72 hours after exposed of a mixture of bleach and detergent, The amount of 1 cc, 20 and 35 minutes in duration Between experimental and control groups (\* $P \leq 0.01$ , \*\*  $P \leq 0.001$  compared with control group) (n=6) (B+D  $\rightarrow$  Bleach + Detergent)

Table1: Comparison of mean  $\pm$  SEM thickness of Mucosa Layer conjunctiva tissue between experimental group with control group after exposed of a mixture of bleach and detergent, The amount of 1 cc

After 35 minutes Exposed aerosol (Mean $\pm$ SEM)	After 20 minutes Exposed aerosol (Mean $\pm$ SEM)	groups Exposed aerosol
0/47 $\pm$ 19/98	0/47 $\pm$ 19/98	control
*0/5 $\pm$ 15/85	*0/51 $\pm$ 16/56	After 24 minutes
*24/0 $\pm$ 12/36	*0/39 $\pm$ 13/26	After 48 minutes
*0/31 $\pm$ 9/63	*0/42 $\pm$ 10/36	After 72 minutes

Number in groups is 6. \*  $p \leq 0/001$  in comparison control groups.

Table2: Comparison of mean  $\pm$  SEM thickness of Lamina mucosa conjunctiva tissue between experimental group with control group after exposed of a mixture of bleach and detergent, The amount of 1 cc

After 20 minutes Exposed aerosol (Mean $\pm$ SEM)	After 20 minutes Exposed aerosol (Mean $\pm$ SEM)	groups Exposed aerosol
27/0 $\pm$ 81/84	27/0 $\pm$ 81/84	control
22/0 $\pm$ 15/84	27/0 $\pm$ 48/84	After 24 minutes
* *29/0 $\pm$ 98/82	31/0 $\pm$ 83/83	After 48 minutes
* *29/0 $\pm$ 98/81	*34/0 $\pm$ 11/83	After 72 minutes

Number in groups is 6. \*  $p \leq 0/01$ , \*\*  $p \leq 0/001$  in comparison control groups.

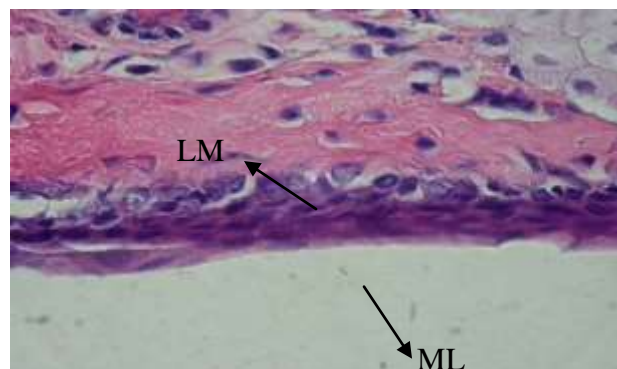


Figure 3: The photomicrograph of Mucosa layer and Lamina mucosa conjunctiva tissue in group 6 after 72 hours exposed aerosol (coloring: H & E microscopic magnification: 100  $\times$ ) decrease in the thickness of Mucosa layer conjunctiva tissue can be seen in this picture. ML=Mucosa Layer, LM=Lamina Mucosa.

## DISCUSSION

According to studies, inhalation of chlorine gas and its reaction with water in body tissues cause the release of free oxygen radicals are highly unstable molecules and the tendency to take electrons from the molecular, the molecules self-sacrifice this process causes the flow to become a free radical chain reactions can be production of free radicals [15]. External stimuli can cause the mitochondrial electron transport chain on the cell its original position and reduce oxygen free radical production is affected and increase free radical production [8]. The creation of free radicals, 4 point of the body that are damage to lipid compounds, proteins, DNA and have harmful effects are Lysosome [15]. Since the cell membranes of unsaturated fat are made, these molecules are susceptible to damage by the free radicals are these lipid molecules so that cause hardening of cell membranes, which blocks the ability of cells to receive nutrients and cellular exchanges will lose this is accompanied by cell death [15]. DNA structure in an open rupture in the sequence of purine and the DNA structure are destroyed. In protein building caused degradation amino acids of pre-protein and thus the degradation structure has to follow and free radical damage to membrane Lysosomes, and the enzyme produced in these been released into the cell cytoplasm cellular components and thus can digest [8]. The study of microscopic sections of mouse Mucosa Layer and Lamina mucosa conjunctiva tissue taken many histopathological changes seen in experimental animals compared with control group. Changes include the significant decrease of thickness in the Mucosa layer and Lamina mucosa conjunctiva tissue.

This can be explained by the to the effects of free radicals generated during this study extended According to findings by the come the highly reactive free radicals, these molecules are can

reaction side cellular companies also have devastating effects on their own.

## REFERENCES

1. Haghghatpajoh H., Jamshidi R. Identifying and detergent technology, first printing, Publishing Mobtakeran, 2006. 15-9.
2. Rojhan M. Color Atlas of Histology and practical, first printing, Soroush, 1992. 291-309.
3. Blanc P.D., Galbo M., Hiatt P., Olson K.R. Morbidity following acute irritant inhalation in a population based study. JAMA, 1991. 266, 664-9.
4. Barrow C.S., Alarie Y., Warrick J.C., Stock M.F. Comparison of the sensory irritation response in mice to chlorine and hydrogen chloride. Arch Environ Health. Mar-Apr, 1977. 32(2), 68-76.
5. Bagchi K., Puri S. Free radicals and anti oxidants inhalation and disease, Eastern Mediterranean Health Journal, 1998.(45) 350-360.
6. Dence C.W., Douglas W., Pulp Bleaching, Textile Association of Pulp and Paper Industry, 1996. 65-69.
7. Das R., Blanc P.D. Chlorine gas exposure and the lung: a review. Toxicol. Ind. Health, 1993. 9(3), 439-55.
8. Florian M., The nature and mechanism of superoxide production by the electron transport chain, Journal of Association of Physicians of India, 2003. 4, 227-253.
9. Grime k., Class A. Laundry Bleaches and Activators, Chemistry and Industry, 1990. 647- 49.
10. Gapany-Gapanavicius M., Yellin A., Almog S., Tirosh M., Pneumomediastinum. A complication of chlorine exposure from mixing household cleaning agents. JAMA, Jul 16, 1982. 248(3), 349-50.
11. Gilchrist H.L., Matz PB., The residual effects of warfare gases: the use of chlorine gas, with report of cases. Med. Bull. Vet. Adminis., 1933. b,9, 229-270.

12. Hedges J.R., Morrissey W.L., Acute chlorine gas exposure. *JACEP*, Feb, 1979. 8(2), 59-63.
13. Hayaishi O., Enzymatic hydroxylation. *Am Rev. Biochem*, 1969. 38, 21-44.
14. Harman D., Role of free radicals in aging and disease. *Annals of New York Academy of Sciences*, 1992. 673,126-141.
15. Han D., Williams E., Cadenas E., Mitochondrial respiratory chain-dependent generation of superoxide anion and its release into the intermembrane space. *Biochem. J*, 2001. 353, 411-6.
16. Jiang K., Buckley L., Morgan k., Pathology of Toxic Responses to the RD<sub>50</sub> Concentration of Chlorine Gas in the Nasal Passages of Rats and Mice, *Toxicol Appl Pharmacol* (71),225-236.
17. Jones R.N., Hughes J.M., Glindmeyer H., Weill H., Lung function after acute chlorine exposure. *Am. Rev. Resp. Dis.*, Dec, 1986. 134(6), 1190-5.
18. Klonne D., Ulrich C., Riley M., Hamm T., Morgan K., Barrow C., One-year inhalation toxicology study of chlorine in rhesus monkeys, *Fundam. Appl. Toxicol.*, 9. 557-572.
19. Malcolm B.H., Poisoning Due to Chlorine Gas, *CARPIN*; 81,42-45.
20. Martinez T.T., Long C., Explosion risk from swimming pool chlorinators and review of chlorine toxicity. *J. Toxicol. Clin. Toxicol.*, 1995. 33(4), 349-54.
21. Patel R.P., The biochemistry of nitric oxide and peroxynitrite implications for mitochondrial function. In Packer L, Cadenas E *Understanding the process of aging: the roles of mitochondria, free radicals, and antioxidants*. New York, NY Marcel Dekker 2003. 45,39-56.
22. Schwartz D.A., Acute inhalational injury. *Occup. Med.*, Apr-Jun, 1987. 2(2),297-318.
23. Trotman E.R., Textile scouring and bleaching Saudi Public, *Textile Scouring and Bleaching*, 1968. 89-94.

