

### Reference

1. Adams, HR, Opioid agonists & antagonists, Veterinary Pharmacology & Therapeutics. (8th. Edn.), Ames, Iowa, Iowa state press. PP: 268-276.
2. Berglund, LA., Millard, WJ., Gabriel, SM., and Simpkins, JW (1990) Opiate- thyroid hormone interactions in the regulation of thyrotropine secretion in the rat. *J. Neuroendocrinol.*, **52(3)**:303-308.
3. Bhaskaran, M., Reddy, K., Sharma, S., et al. (2001) Morphine-induced degradation of the host defense barrier: role of macrophage injury. *J Infect Dis*, **184**:1524-1531.
4. Cho, C.H., Wu, K.K., Wu, S., Wong, T.M., So, W.H.L., Liu, E.S.L., Chu, K.M., Shin, V.Y., Ye, Y.N and Wong B.C.Y (2003) Morphine as a drug for stress ulcer prevention and healing in the stomach. *J. European Journal of Pharmacology.*, **460**:177-182
5. Dinari, G., Ashkenazi, S., Marcus, H., Rosenbach, Y and Zahavi, I (1989) The effect of opiates on the intestinal immune response to cholera toxin in mice. *J. Digestion*, **44**:14-19.
5. Frenklakh, L., Bhat, RS., Bhaskaran, M., Sharma, S., Sharma, M., Diana, A. and Singhal, PC. (2006) Morphine-Induced Degradation of the Host Defense Barrier Role of Intestinal Mucosal Injury. *Digestive Diseases and Sciences*, **51(2)**:318-325.
6. Harari, A., Weisbrodt, NW. and Moody, FG.(2006) The effect of morphine on mast cell-mediated mucosal permeability Surgery, **139**:54-60.
7. Hilburger, M. E., Adler, M. W., Truant, A. L., et al (1997) Morphine induces sepsis in mice. *J Infect Dis*, **176**:183-187.
8. Katzung, BG (2004) Opioid analgesics & antagonists: Basic & Clinical Pharmacology. 9TH. Edn., McGraw-Hill, pp: 492-498.
9. Kimberly, A., Ballard & Trisha, C., Pellegrino & Norma, C., Alonzo & Alexandria, L., Nugent., Barbara, M., and Bayer (2006) Enhanced Immune Sensitivity to Stress Following Chronic Morphine Exposure. *J. Neuroimmune Pharmacol*, **1**: 106-115.
10. Nalbandian, H., Sheth, N., Dietrich, R and Georgiou, J (1985) Intestinal ischemia caused by cocaine ingestion: report of two cases. *J. Surgery*, **97(3)**:374-6.
11. Niazi, M., Kondru, A., Levy, J and Bloom AA (1997). Spectrum of ischemic colitis in cocaine users. *J. Dig Dis Sci*, **42(7)**:1537-1541.
12. Nurten, K and Bilgo K (2004) Intravesical analgesia for ambulatory urologic procedures: a histopathologic study. *J. Ampulatory surgery*, **10(4)**:201-203.
13. Pasternak, GW (1993) Pharmacological mechanisms of Opioid analgesics. *J. Clinical Neuropharmacol*, **16**:1-18.
14. Rang, HP., Dale, MM., Ritter, JM and Moore PK (2004) Analgesic drugs: Pharmacology. 5<sup>th</sup>. Edn., Churchill Livingstone, pp: 562 -565.
15. Roy, S., Cain, KJ., Charboneau, RG. And Barke, RA., 1998. Morphine accelerates the progression of sepsis in an experimental sepsis model. *Adv Exp Med Biol*, **437**:21-31.
16. Swaab, DF (1995) Sexual differentiation of the human hypothalamus in relation to gender and sexual orientation, *J. Trends neurosci*, **18**:265-270.
17. Tal, EL., Koranyi, Z and Kovacs and Endroczi, E (1984) Short-term effect of morphine on the thyroid gland in male rats. *J. Acta Endocrinol (Copenh)*, **105(4)**:511-514.
18. Tharp, MD., Kagey-Sabota, A. and Fox, CC. et al.(1987) Functional heterogeneity of human mast cells from different anatomic sites: in vitro responses to morphine sulfate, *J Allergy Clin Immuno*, **179**:646-653.
19. Yilmaz, B., Konar, V., Kutlu, S., Gezen, MR and Kelestimur. H. (1999) Influence of chronic morphine exposure on serum LH, FSH, Testosterone levels and body and Testicular weights in the developing male rats. *J. Achieves of andrelogy*, **43**:189-196.
20. Yoshida, S., Tajiri, T., Yahara, T., Yoshizumi, T., Tanaka, K., Muraoka, T., Yamasaki, K and Shirouzu, K. (2000) Administration of opiate receptor antagonist inhibits mucosal atrophy of the gut in fasting rats. *J. Surg*, **93(1)**:177-81.



a significant decrease in body weight was seen. It seems that starvation elevates concentration of the morphine in CNS. This increase leads to intestinal mucosal atrophy and weight loss in the mice subsequently. Elevation of morphine concentration in brain stimulates proteolysis rate (Yoshida et al 2000).

Weight of control group at the age of 3-6 weeks after 24 hours of unfeeding did not show significant difference when it was compared with other groups. Also the test group body weight at the age of 3-6 weeks did not show any significant difference with the sham and control group. Unfortunately, the most of previous studies worked on mature mice. Therefore, we could not analyze this problem in the immature group (3-6 weeks of the age). One reason for that may be due to slow growth of mice before maturation. So morphine cannot affect body weight in this age group.

By comparison sham and control group body weight, test group body weight at the age of 6-9 and 3-12 weeks had a significant difference. These results suggested that the chronic morphine administration decreased body weight (Tal et al. 1984; Berglund et al. 1990; Pasternak. 1993; Nurten et al. 2004) in period of maturity. Because morphine causes decrease in nutrition, physical activity and digestive system function in the addicted animal (Swaab 1995; Yilmaz et al. 1999). Morphine slows down motility of digestive system, peristaltic waves and HCL secretion and also increases the tonicity of stomach and duodenum. In addition, it could delay the emptiness of the stomach (Katzung. 2004; Range et al. 2004). Opioid infusion such as morphine reduces villus height and causes mucosal atrophy (Yoshida et al. 2000). All above mechanisms lead to weight losses in mice.

On the other hand, morphine activates release of thyroid hormones that increase metabolism subsequently. In this situation, Morphine consumption should be acute (Tal et al, 1984).

#### 2- Histomorphological changes in intestinal tissue

Our results showed that the chronic exposure to oral morphine leads to the invasion of mononuclear cells to duodenum, ileum, jejunum and colon mucosa. It was reported that the morphine not only has the inhibitory effect on digestive system but also affects the intestinal immunity response. Morphine attracts inflammatory cells toward the intestine and changes intestinal mucosal thickness (Chi H et al. 2003). This effect is done by the opioid receptors (especially  $\mu$ -receptor) and is inhibited by naloxane (Dinari et al. 1989). Also infiltration of mononuclear cell to ileum may be due to Payer patches stimulation existed in the ileum. But some evidences exist that opiates are immunomodulatory (Kimberly et al. 2006).

Since the most important morphine receptor is receptor, low-dosed morphine extensively affects

these receptors, while high-dosed morphine only stimulates other receptors (like  $\kappa$  and  $\delta$  receptors) that they have little importance (Adams. 2001). So low dose morphine (0.01mg/dl) leads to major histological changes.

Decrease of villus height and villus intensity in test group compared to sham and control group was other variation. Consistent with our study, Yoshida et al (2000) reported that morphine infusion reduced villus height, mucosal weight and protein content in jejunum in Sprague-Dawley rats.

Colonial mucosa showed invasion of mononuclear cell, hyperemia, and increase in Goblet cell size and secretion, because chronic administration of this drug slows GI tract motility (Harari et al 2006), so the body is not resistant to alimentary parasites. Thus increase in secretary activity and size of Goblet cell should be an immunologic reaction (Dinari et al. 1989). Niazi et al (1997) observed bleeding, ulcer, pseudo polyp and inflammation in mucosal layer of colon in cocaine addict. The chronic morphine consumption can cause ischemia and finally gangrene of the intestine. High number of leukocytes in gangrene area was reported (Nalbandian et al. 1985). Vessel in this experiment were hyperemic no hemorrhagic. Our experiment and other research on the morphine (Frenklakh et al 2006, Harari et al 2006, Yoshida et al 2000) don't demonstrate any necrosis or gangrene in intestine about morphine.

Low mononuclear cell accumulation in 3-12 weeks of age group may be due to adaptive change that occurs after long-time drug consumption. On the other hand, in 3-6 weeks of age group, immune system has been weak and so couldn't response to morphine administration.

#### **In summary, we concluded that:**

1- Long- termed use of morphine has led to weight losses in mice.

2- Morphine caused histomorphological change in small and large intestine in all age groups.

3- Marked and slight histomorphological change was in 6-9 and 3-12 weeks of age group respectively.

4- Most important histomorphological change was mononuclear cell invasion to mucosa

Regard to this research, further studies are needed for evaluation morphine and other opiates side effects on alimentary tract and its accessory gland such as salivary glands, pancreas and other secretary gland. We suggested that the chronic morphine consumption must be limited or inhibitory compounds such as naloxane accompany with morphine administration. Although naloxane and similar drug have side effects that limited their consumption.



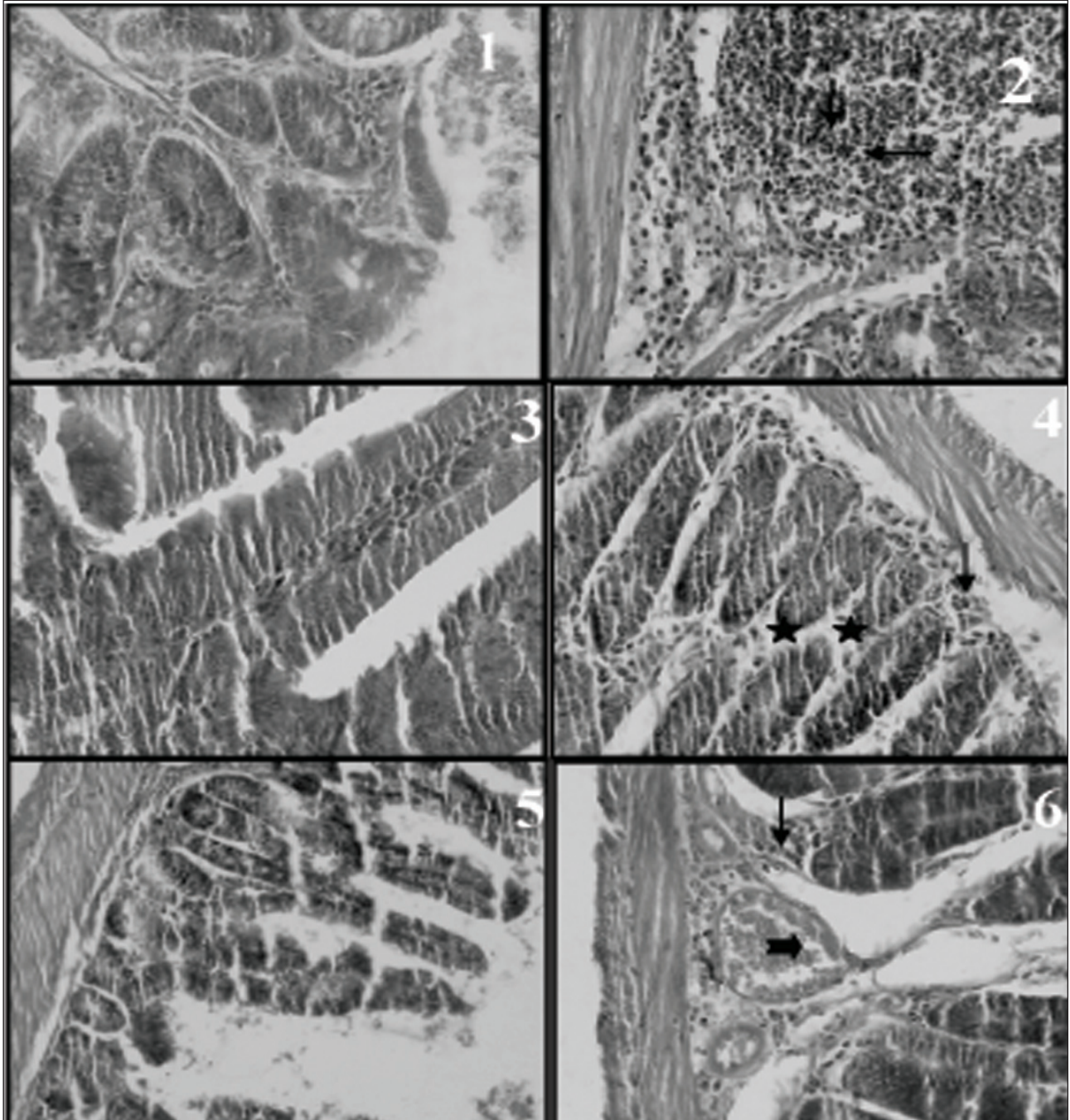


Figure 1- Histological section of intestine in control and test groups. 1- Ileal tissue, 3-6 weeks of age control group (40 x). 2- Ileal tissue, 3-6 weeks of age test group (0.1mg/dl) (40 x). Mononuclear cell invasion is observable (arrows). 3- Duodenal tissue, 6-9 weeks of age control group (40 x) 4- Duodenal tissue, 6-9 weeks of age test group (0.01mg/dl) (40 x). Mononuclear cell invasion (arrow) and shortness of villous (stars) are shown. 5- Jejunal, tissue, 3-12 weeks of age control group (40 x). 6- Jejunal, tissue, 3-12 weeks of age test group (0.1mg/dl) (40 x). Mononuclear cell accumulation and hyperemia (bold arrow) are shown.

Lieberkuhn. Also, accumulation of mononuclear cells in 6-9 weeks and 3-12 weeks of age group was maximum and minimum respectively.

### Discussion

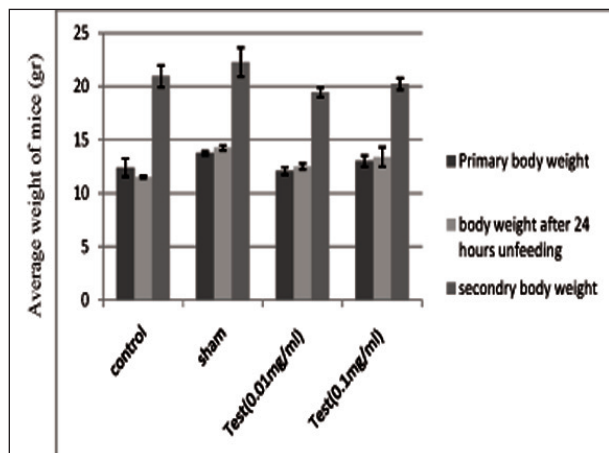
The effect of the chronic exposure to oral morphine on body weight and intestinal mucosal tissue in mice

strain Balb/c was examined. Considering that morphine usually is consuming in two different kinds of dosages (0.1mg/dl and 0.01mg/dl) in practice, these two dosages were used in this study.

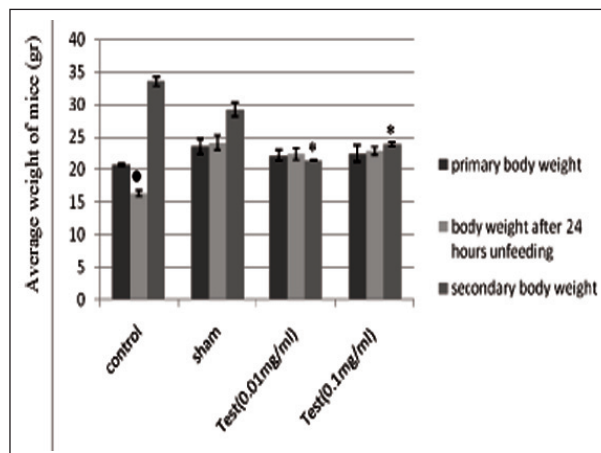
#### 1-Body weight of mice

According to this study, after 24 hours of unfeeding in the control group at the age of 6-9 week,

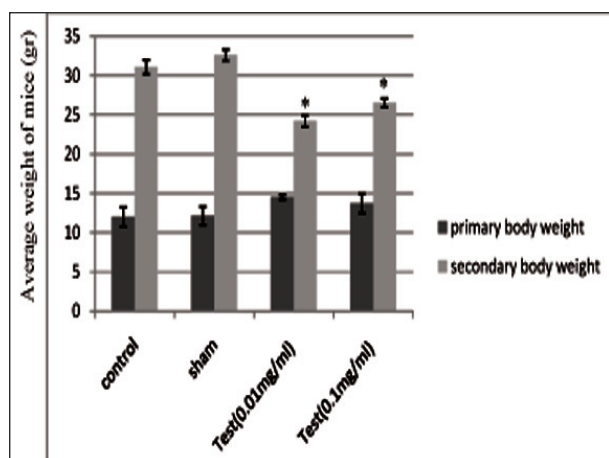




Graph 1- Comparison of the body weight (mean  $\pm$  SD) in 3-6 weeks age group. Body weight difference after 24 hours unfeeding and secondary body weight were not significant ( $p > 0.05$ ).



Graph 2- Comparison of the body weight (mean  $\pm$  SD) in 6-9 weeks age group. \* There was a significant difference between control group body weight and other groups after 24 hours unfeeding ( $p < 0.05$ ). \* There was a significant difference in the secondary body weight between test groups and other groups ( $p < 0.01$ ).



Graph 3- Comparison of the body weight (mean  $\pm$  SD) in 3-12 weeks age group.\* Body weight differences between test groups and sham or control group were significant ( $p < 0.01$ ).

## Results

### 1-Effect of morphine on body weight:

This study showed that control group weight at the age of 6-9 weeks after 24 hours unfeeding was lower than other groups at this age ( $p < 0.05$ ). While the control group weight at the age of 3-6 weeks after 24 hours unfeeding was not significant in compared with the other groups at the 3-6 weeks age class ( $p > 0.05$ ) (Graph 1, 2). In 3-6 weeks of age group, difference between the test group weight and sham or control group weight was not significant ( $p > 0.05$ ). There was a same condition between the control group and the sham group weight ( $p > 0.05$ ) (Graph 1). In 6-9 and 3-12 weeks of age groups, weight difference between test group and sham or control group was significant ( $p < 0.01$ ,  $p < 0.01$ ). Control and sham group did not show any significant differences ( $p > 0.01$ ,  $p > 0.05$

respectively) (Graph 2 and 3).

### 2- Histomorphological changes in intestinal tissue

After sampling and preparation of histological film, histomorphological variations in large and small intestine of female mice strain Balb/c were examined. No foreign pathogens (Bacteria, fungus, parasites etc) were seen in histological mucosa in control, sham, and test groups.

All Control and sham groups did not show any important histological changes. Major layers of the intestine (mucosa, submucosa and external-internal muscular layer) were distinguishable. Villous height and shape were normal. Simple columnar epithelium of the intestine did not show any misshapeness. (Figure 1-1, 1-3, 1-5).

Mononuclear cells invasion to duodenum, ileum, and jejunum and colon mucosa was seen in all test groups of different age exposed to two different morphine dosages (0.01mg/dl, 0.1mg/dl). Hemorrhage, necrosis or other granulomatose reaction were not visible (Figures 1-2, 1-4, 1-6). Increase in mononuclear cells number in lamina propria layer of colon was noticeable in 6-9 and 3-12 weeks of age group (Figures 1-4, 1-6).

In addition, villus height and intensity in 6-9 weeks of age test group were lower than control and sham group (Figure 1-4). Low morphine dosage (0.1mg/dl) caused major histological changes in intestine tissue. Hyperemia and increase in Goblet cells size and secretion in colon existed noticeably (6-9 weeks of age group, not shown in pictures).

In jejunum, hyperemia and accumulation of mononuclear cell was clear (Figure 1-6). Other results that were obtained from this study showed that any dosage of morphine (0.01mg/dl or 0.1mg/dl) did not affect the intestinal glands such as Brunner or



## Introduction

Morphine is main alkaloid of opioids analgesic factors (Adams, 2001) which morphine-6-glucuronide and morphine-3-glucuronide are its major metabolites. In clinical practice, the morphine exerts its principal pharmacological effect on the central nervous system and gastrointestinal tract (Rang et al., 2004). It seems that morphine and other opioids compound have major harmful effects on intestinal tissue (Frenklakh et al 2006, Harari et al 2006, Yoshida et al, 2000). Subsequently, pathological changes in mucosa lead to weight loss in animal (Yoshida et al., 2000). It was documented that opiate addicts have many infectious diseases. Because not only opioids compound (especially morphine) induce intestinal stasis and subsequently bacterial overgrowth but also can translocate bacteria from intestinal lumen to the splanchnic lymph nodes (Harari et al 2006, Roy et al 1998). One of the best way to the recognition of the effect of chronic consumption morphine (or other similar compound) on intestinal mucosa is to examine intestinal histopathological changes and involved inflammatory cell (Frenklakh, et al 2006, Tharp et al 1987). This pathological injury due to the inflammatory cell has a main role in pathogenesis of morphine effects on intestinal tissue (Bhaskaran et al 2001, Hillburger et al 1997). But unfortunately, histopathological changes and roles of other inflammatory cell in literature haven't been examined well and only effects of some inflammatory cell were explained. For example, it was demonstrated that morphine could stimulate NO generation in intestinal macrophages, or could activate mast cell of GI tract. These mechanisms lead to intestinal ulcer and increase permeability of intestinal lumen to foreign pathogen, respectively (Frenklakh et al 2006, Harari et al 2006). In this study, we tried to find out the effect of long-termed use of opioids morphine (opioids) on histomorphological structure of intestinal tissue and subsequently the growth of animal.

## Material and methods

In this study, we used three groups of female mice strain Balb/C (sell from Razi institute, Tehran, Iran); 3-6 weeks of age (premature), 6-9 weeks of age (mature) and 3-12 weeks (from premature to full mature). For better detection, mice were been weighted and marked with fixative Bowen's solution (picric acid [75cc] + formalin10% [25cc] + glacial acetic acid [5cc]- all material from Merck company-Germany). The plastic cages for keeping mice were covered with straw and sawdust and cleaned weekly. The experiment was done in 21 centigrade, 45-55% humidity and 12 hours dark and 12 hours light period. The mice were fed with commercial plates. Before the start of experiment, the mice were randomized in 12

groups; 6 test groups, 3 sham groups and 3 control groups. There were 20 mice in each test group. The control and sham groups, with 5 mice in each, selected from three age groups. The control group consumed purified water, while the sham group consumed water and 5 mg/kg sugar and the last group were received water with 5 mg/kg sugar and morphine (Alborz daru company, Iran) (0.01 mg/ml and/or 0.1 mg/ml). For preparation of 0.01mg/ml and 0.1mg/ml of morphine solution in water, first two days morphine dosages were (0.002) and (0.02 mg/ml), second two days (0.005) and (0.05 mg/ml), third two days (0.008) and (0.08 mg/ml) and finally (0.001) and (0.01 mg/ml) from seventh day to the end of study. It is necessary to note that all mice consumed 5 ml of water in 24 hours. For resolving morphine bitter taste sugar were added to the water. The grooming period for premature and mature group were 21 days and for last group was 69 days.

For the evaluation of the effect of stress on the body weight, control groups at the age of 3-6 and 6-9 weeks were unfed 24 hours at beginning of the experiment and then by elapsing this time, mice of these groups were weighted.

At the end of the study, mice were weighted and then anaesthetized with Diethyl ether (Merck company, Germany). Incision from mandible to anus was performed by scissors and then extracted GI tract. After washing and cleaning the intestine with normal saline, the same incision was performed on small and large intestine and then intestine was plunged in 10% Buffer-formalin. After 24 hours, the buffer-formalin was changed and the samples were placed in refrigerator until histological section was done.

## Pathological techniques

Different parts of gastrointestinal tract (duodenum, jejunum, ileum & colon) were examined. Blocks of tissue about 2 x 2 cm in size were fixed in 10% neutral buffered formalin and then embedded in paraffin wax. Sections were cut at 5  $\mu$ m and stained by Mayer's Haematoxylin and Eosin (HE). A veterinary pathologist unbiasedly examined the sections. Sections from all the experimental groups were controlled for any foreign pathogen invasion such as gram negative bacteria, intestinal parasites, pathogen fungus and etc.

## Statistical Analysis

By means of Prism3 statistical software, data were analyzed by one-way analysis of variance (ANOVA) and Duncan test. Also the histomorphological changes of small intestine were described and recorded. A P value <0.05 was considered significant.



# Effect of Chronic Administration of Opioids (Morphine) on Growth and Intestinal Mucosa in Mouse Strain Balb/c

Habibian, S.<sup>1</sup>, Zamani Ahmadmahmoodi, M.<sup>2\*</sup>, Shadkhist, M.<sup>1</sup>, Khaksar, E.<sup>3</sup>, Rashidi, M.<sup>1</sup>, Ziaei, B.<sup>2</sup>

<sup>1</sup>Department of basic science, faculty of veterinary medicine, Shahrekord University, Shahrekord- Iran.

<sup>2</sup>Department of clinical science, faculty of veterinary medicine, Tehran University, Tehran- Iran.

<sup>3</sup>Department of clinical science, faculty of veterinary medicine, Islamic Azad University, Garmsar Branch, Garmsar- Iran.

\*Correspondence: mhd\_zamanh\_2006@yahoo.com

دریافت مقاله: ۶ خرداد ۸۹، پذیرش نهایی: ۲۰ مهر ۸۹

## Abstract

Apart from the nervous system, the digestive system has the maximum opioids receptors which it indicates importance of the opioids in this system. It seems that morphine and other opioids compound have major harmful effects on intestinal tissue. Purpose of this study is to examine of the long-termed use of the morphine on growth and histomorphological structure of digestive system in mice strain Balb/c. Some mice were selected from three age groups (premature, mature and from premature to full mature). One hundred fifty mice (at the age of 21 days) were divided to 12 groups randomly. Groups consisted of six test groups (20 mice in each group), three control groups (5 mice in each group) and three sham groups (5 mice in each group). Control groups were maintained on stock dieted of tap water while sham groups dieted with tap water and sugar (5mg/ml). Test groups also used tap water, sugar and two different dosages of morphine (0.01mg/ml or 0.1mg/ml). Our study showed that in all tests groups, the chronic administration of escalating doses of the morphine caused decrease of the weight of mice. In addition, the long-termed use of morphine caused histological changes in small intestine and colon in all the groups of age. Invasion of mononuclear cell (especially lymphocyte) to mucosa was the most important histological change. In addition, villous height and intensity also decreased. This study suggested that the chronic consumption of opioids causes pathological change in gastrointestinal system. *Vet. Res. Bull. 6,2:176-181, 2011.*

**Keywords:** digestive system, growth, intestinal mucosa, mononuclear cell, morphine.

## اثرات مصرف مزمن اپیوئیدها (مرفین) بر روی رشد و مخاط روده‌ای در موش

### سوری

نام نویسندگان: سعید حبیبیان<sup>۱</sup>، محمد زمانی احمد محمودی<sup>۲\*</sup>، محمد شادخواست<sup>۱</sup>، احسان خاکسار<sup>۱</sup>، محسن رشیدی<sup>۱</sup>، بیژن ضیایی<sup>۲</sup>

- ۱- استادیار گروه علوم پایه دانشکده دامپزشکی دانشگاه شهرکرد، شهرکرد- ایران.
- ۲- دستیار تخصصی کلینیکال پاتولوژی دانشکده دامپزشکی دانشگاه تهران، تهران- ایران.
- ۳- دستیار تخصصی داخلی دامهای کوچک دانشکده دامپزشکی دانشگاه آزاد واحد گرمسار، گرمسار- ایران.
- ۴- دستیار تخصصی داخلی دامهای کوچک دانشکده دامپزشکی دانشگاه تهران، تهران- ایران.
- ۵- دانش آموخته دامپزشکی دانشکده دامپزشکی دانشگاه شهرکرد، شهرکرد- ایران.

### چکیده

دستگاه گوارش پس از دستگاه عصبی دارای بیشترین میزان رسیپتورهای اپیوئیدی در بدن است که نشان دهنده کارایی زیاد اپیوئیدها در این دستگاه می باشد. بنظر می رسد که مرفین و سایر ترکیبات اپیوئیدی باعث آسیب های جدی به بافت مخاط روده می شود. برای پی بردن به تاثیر مصرف طولانی مدت مرفین، شاخصترین داروی ضد درد اپیوئیدی، بر ساختمان هیستومرفولوژیکی دستگاه گوارش، مطالعه حاضر بر روی موش سوری در ۳ رده سنی قبل از بلوغ (۳-۶ هفته)، طی بلوغ (۹-۱۲ هفته) و قبل از بلوغ تا بلوغ کامل (۱۲-۳ هفته) انجام شد. تعداد ۱۵۰ سوسور موش سوری ماده نژاد Balb/c در سن ۲۱ روزگی بطور تصادفی به ۱۲ گروه به شرح زیر تقسیم شدند. ۶ گروه آزمایشی در هر گروه ۲۰ سوسور موش، ۳ گروه شم در هر گروه ۵ سوسور موش و ۳ گروه کنترل در هر گروه ۵ سوسور موش. گروه های کنترل تنها از آب لوله کشی استفاده نمودند در حالیکه گروه های شم آب لوله کشی به همراه ۵mg/ml شکر و گروه های آزمایشی آب لوله کشی به همراه ۵mg/ml شکر به اضافه مرفین با دوز ۰/۱mg/ml و ۰/۱mg/ml مصرف کردند. نتایج نشان داد که در تمام گروه های آزمایشی، مصرف مزمن مرفین باعث کاهش وزن موش ها می شود. علاوه بر این مصرف مرفین در هر دو دوز در همه رده های سنی باعث تغییرات بافتی در قسمتهای مختلف روده باریک و کولون موش می شود؛ که شایعترین تغییر بافتی هجوم سلول های تک هسته ای به مخاط قسمت های مورد بررسی می باشد. بعلاوه ارتفاع و تراکم ویلوس های روده ای نیز کاهش یافت. نتایج تحقیق حاضر پیشنهاد می کند که باید تغییرات پاتولوژیک بافتی را که بسته به سن موش ها و دوره زمانی مصرف آن ها متفاوت می باشد در نظر گرفت. پژوهشنامه دامپزشکی، ۱۳۸۹، دوره ۶، شماره ۲، ۱۸۱-۱۷۶.

واژه های کلیدی: دستگاه گوارش، رشد، مخاط روده، سلول های تک هسته ای، مرفین.

