

Possibility of Early Detection of Bovine Mastitis in Dairy Cows Using Thermal Images Processing

Research Article

M.R. Golzarian^{1*}, H. Soltanali¹, O. Doosti Irani¹ and S.H. Ebrahimi²

¹ Department of Biosystems Engineering, Faculty of Agriculture, Ferdowsi University of Mashhad, Mashhad, Iran

² Department of Animal Science, Faculty of Agriculture, Ferdowsi University of Mashhad, Mashhad, Iran

Received on: 28 Nov 2016

Revised on: 16 Mar 2017

Accepted on: 15 Apr 2017

Online Published on: Dec 2017

*Correspondence E-mail: m.golzarian@um.ac.ir

© 2010 Copyright by Islamic Azad University, Rasht Branch, Rasht, Iran

Online version is available on: www.ijas.ir

ABSTRACT

Bovine mastitis (BM) is a prevalent condition on dairy farms, affecting both livestock health and reducing profitability. This study investigated the feasibility of diagnosing BM in Holstein dairy cattle using thermography. To increase the detection between healthy cattle and unhealthy one and to better compare the results from thermal images, a number of parameters including somatic cell count (SCC) and California mastitis test (CMT) were adopted. The result of non-parametric Spearman's Rho test showed that there was an inverse correlation ($R=-0.97$) between SCC factor and milk production records. Bovine Mastitis diagnosis results obtained from processing thermal images showed that the average temperature difference between unhealthy and healthy tissues was $0.44\text{ }^{\circ}\text{C}$. The detection accuracy of this method was 57.3%. The results from processing the thermal images showed that the thermal imaging camera was able to detect small temperature difference on the skin sometimes due to the effects of factors, such as non-uniform light irradiation and the presence or absence of hair or skin lesions on udder surface, which are not necessarily the studied factors. Therefore, it is suggested that parameters such as udder's touching to groin, hair on udder, reduced light effect and skin lesions in order to improve the precision in the thermographic diagnosis of BM also be controlled future studies.

KEY WORDS animal health, bovine mastitis, California mastitis test, somatic cell count, thermal image.

INTRODUCTION

As the most important sources of protein and dairy products, livestock farms play an important role in the food security of society. Accordingly, addressing limitations of this sector should be a prime concern. Livestock health, as an important factor in the sustainable production of dairy products, is effective in the sector's dynamics and productivity (Windig *et al.* 2005). Dairy cows are exposed to a wide range of bovine diseases. Bovine mastitis (BM) is one of the most important and prevalent diseases affecting livestock health. A large number of cattle, particularly in Iran, are infected with BM. There are several parameters influ-

encing its development and spread including infectious factors (e.g. microorganisms like bacteria) and predisposing factors (e.g. environment, milking system type, and farm management system; Heringstad *et al.* 2000; Hovinen *et al.* 2008). Timely diagnosis of BM using highly precise, rapid techniques can contribute to both maintaining the livestock health and reducing quantitative and qualitative losses of milk production. Currently, there is scant information on quantitative milk losses from BM (also known as the silent disease) in Iran. A study by Bolourchi *et al.* (2006), however, showed that such losses vary between 1 to 25 percent resulting in the annual losses of about 150 thousand tons in the country. Besides reducing milk output of a cow by 70%

during a milking period, BM can also have irreparable consequences for milk quality, dairy calves and most importantly for human health as it causes milk to be contaminated with blood and discolored (Bolourchi *et al.* 2006). To enhance the profitability and improve dairy cow survival and health in Iran, it is important to implement high accuracy, rapid BM detection techniques, particularly on farms. Extensive research has been done on BM diagnosis and detection. Generally, for diagnosing BM in cows, there are multiple methods classified as conventional and novel approaches (Viguiet *et al.* 2009). Conventional methods include microbiological tests, California mastitis test (CMT), electrical conductivity test, somatic cell count (SCC) and also bacterial culture. Novel approaches, however, include thermal images processing captured by thermal cameras, using ultrasonic waves as in sonography also, using chemical sensors and biosensors. Among the literature on using conventional methods, Ayareh and Mirzaei (2014) studied the parameters effective in milk somatic cells (SC) in cows with / without BM history. They reported that cows with a BM history had higher concentrations of SC. Najafi and Mortazavi (2009) investigated the effect of SCs on milk composition in dairy farms of Khorasan-e Razavi province of Iran. Their results suggested that an averaged SCC/mL milk was at least 419000 and at most 465000 SCC. California mastitis test (CMT) is another conventional method widely used in dairy farms, which measures the difference in milk density. This is a rapid diagnostic method. A disadvantage of CMT is in interpreting its results where the high level of expertise is required (Ghorbanpour *et al.* 2007). Electrical conductivity test is also another technique used for diagnosing BM clinically (observing disease signs visually). It was first introduced in 1940 for diagnosing BM (Davis *et al.* 1943). Ghasemzadeh and Boukaie (2011) used this method for detecting BM. They used a MAS-D-TEC device, which measures the electrical conductivity (EC) of milk for conducting their screening tests. Besides measuring milk EC, this device is also capable of performing CMT. To evaluate performance of their measurements in detecting BM, two indexes (*i.e.* sensitivity and specificity) were used, which were 100 and 92%, respectively. According to the results, there was a relatively high correlation between EC test and CMT results ($r=0.73$), and the device performed successfully in detecting BM. The EC test method can be performed at milking stations, and it can measure EC by promoting factors such as sodium, potassium, calcium, magnesium and chloride. As a drawback, high variations in milk EC can limit its diagnostic accuracy. Healthy milk samples have a normal EC limits from 4 to 6 mS or m Ω . Once milk EC exceeds these limits, it will be a sign of BM (Ferrero *et al.* 2014; Norberg, 2005). Currently, thermal image processing is a novel approach applicable to

dairy farming (McManus *et al.* 2016; Menegassi *et al.* 2015; Cruz Júnior *et al.* 2015; Simões *et al.* 2014). Thermography was used in some of Switzerland's dairy farms for early detection of digital dermatitis (Alsaadod *et al.* 2014). Results from processing a total of 1192 images showed that the maximum temperature was in the coronary band and also in the front and rear of the hooves. Poikalainen *et al.* (2012) used thermal camera to find infrared temperature patterns for cow's body as a health index for livestock in Estonia. Images of 640 × 480 size were taken with a Fluke TiS Thermal imaging scanner (Fluke Corp, US) with 0.1 °C resolution was used for this purpose. Pain sense spots were mostly considered at udders, feet and around skin injuries. Results showed that temperature patterns are not uniform in these areas. Udder temperature variations of pre- and post-milking were small and not statistically significant. That is, using milking machines can affect temperature on udder surface to a given extent. The minimum temperature was observed at hooves. The maximum temperature, however, belonged to the coronary band of hooves.

Schaefer *et al.* (2012) suggested that one of the applications of thermography can be in automatic detection of respiratory diseases in livestock. This is a major condition in beef cattle farming which causes economic losses and affects health and welfare of the cattle. Nikkhah *et al.* (2005) used a combination of visual examination and infra-red (IR) thermography for detecting hoof lesions. Their results suggested that thermography could be used for detecting hoof infections in industrial dairy farms. Most conventional BM diagnosis methods use milk samples, leading to reduced accuracy and speed. Thermal image processing / analysis is a novel non-contact method for this purpose. In fact, the disease severity is determined by analyzing the heat radiated from the injured area (Hovinen *et al.* 2008; Colak *et al.* 2008).

Alejandro *et al.* (2014) reported that thermal imaging can be used for determining thickness variations of dairy goats' udder as a result of mechanical milking. Images were taken from udders before and after the milking process. Healthy animals were separated from unhealthy ones by their milk SCC. Results from processing the thermal images showed that mechanical milking can raise the udder's surface temperature by 1.5 to 6.6 °C. Martins *et al.* (2013) used thermography for examining dairy sheep for mastitis. A FLIR (Forward Looking IR) i-series infrared camera (FLIR inc, US) and the emissivity of 0.97 was employed for this purpose. To this end, sheep were classified into three groups: i) healthy, ii) with clinical mastitis (visually detectable signs), and iii) with subclinical mastitis (visually undetectable signs) groups based on their SCC. Accordingly, if SCC per mL of milk was lower than 200000, the sample was consid-

ered healthy; it was grouped as subclinical if milk SCC was between 200000 to 500000, and it was considered clinical if SCC exceeded 500000. Lateral and medial regions of udder were imaged. Results showed that subclinical mastitis had the highest temperature in both regions, which was due to increased blood flow caused by dilation of blood vessels. [Hovinen *et al.* \(2008\)](#) used infrared thermal imaging to detect BM in Finnish dairy cows. An IR FlexCam (Infrared Solution Inc, US) with 0.90 °C resolution, spectral band of 8 µm to 14 µm, and calibrated from 0 °C to 100 °C was used for this purpose. The camera's distance to udder was 50 cm. Regions were imaged at two lateral and medial angles. Thermal image analysis results suggested that the temperature difference on udder between unhealthy and healthy cattle was 1 to 1.5 °C. There have been other attempts to diagnose BM by thermography ([Barth, 2000](#); [Kamphuis *et al.* 2010](#); [Weschenfelder *et al.* 2013](#); [Stelletta *et al.* 2012](#); [Paim *et al.* 2012](#)). Thermography was used to diagnose dairy cows with BM in Turkey ([Colak *et al.* 2008](#)). Milk samples were examined for BM using both CMT and udder skin temperature measurements. Results revealed a strong correlation ($r=0.73$) between CMT and skin temperature results. There are a large number of BM cases on Iranian dairy farms conversely affecting their health within a sustainable production framework. Moreover, its spread can give rise to increased qualitative and quantitative losses in milk production. Therefore, it is highly essential to develop accurate techniques for timely diagnosis of BM as a fundamental approach. This study investigated the feasibility of BM diagnosis using IR thermal imaging for more accurate detection.

MATERIALS AND METHODS

Study region and cattle selection

This study was an experimental design performed in the Holstein Educational and Research Dairy Farm of Ferdowsi University of Mashhad (FUM) in 2015. This farm has 147 dairy cows divided into three groups of low, high and super-high milk production, according to the amount of milk they produce in a milking period. There were 47 cows in the super-high dairy group. The dairy cows in this group are considered economically most important on the farm and given the high significance of bovine mastitis in this group due to higher frequency of milking, 16 cows out of this group were selected as study samples. Besides, selecting the samples was according to their milk production records, SCC and CMT results.

Diagnosis of BM-unhealthy cattle

Conventional diagnosis methods including CMT, SCC per mL of milk, and also milk production records (milk produc-

tion decline) were used as references for studying the feasibility of BM detection and separation of healthy and unhealthy samples using thermal image processing. The thermal methodology was also validated using the said conventional techniques. To examine the SCC per mL of milk, the latest test results performed on dairy farms were used. According to these tests, the SCC lower than 200000 indicates healthy tissues, the count range between 200000 to 500000 indicates subclinical BM, and higher than 500000 marks clinical BM cases ([Martins *et al.* 2013](#)). BOVI-VET test kit was used for performing CMTs. In this test, 2 mL of test liquid is added to 2 mL of milk from each quarter, and the mixture is then stirred slowly for 20 seconds. The diagnosis in CMT is based on appearance, color as well as the density of the clotted milk. BM-positive samples are scored from one to three. The scores of three cows showed acute BM with high white blood cell (WBC) activity ([Quinn *et al.* 1994](#)).

Imaging procedure

Thermal images were captured by Inf-REC-G120 (NEC Inc, Japan), with the measuring range of -40 to 1500 °C, a resolution of 0.08 °C (at 30 °C), and spectral range of 8 to 14 µm, taking thermal images with the size of 320 × 240 pixels. Emissivity was set as 0.97 on the camera as suggested by [Martins *et al.* \(2013\)](#).

Udder tissue images were taken before and after milking inside the milking station at 26 °C. Imaging was performed at 60 cm from udder. Depending on the udder position, imaged regions included right-rear, right-front, left-rear and left-front. Figure 1 shows thermal image versus non-thermal image of cow udder.

Thermal image processing

Thermal images were analyzed, and the data related to temperature distribution on a given area of udder were examined as dependent factors. Temperature distribution and variation on udders of healthy and unhealthy samples were analyzed. Thermal images were processed using both InfRec Analyzer (NEC Inc, US) and MATLAB-vR-2011a (Mathworks Inc, US). Thermal images were first converted into a 320 × 240 thermal matrix in an attempt to extract the temperatures inside the desired udder regions using a fusion of visible-spectrum and thermal images ([Doosti-Irani *et al.* 2016](#)). Besides extracting temperatures from healthy and unhealthy regions, other regions that might cause experimental errors were also studied. Given that livestock conditions may vary between samples, a block design with three replications was selected in order to find the effectiveness of parameters or error factors in imaging. Data were analyzed in SPSS 19 (IBM Inc, US). Figure 2 shows temperature extraction steps.




Figure 1 Thermal image (a) vs. non-thermal image (b) of cow udder

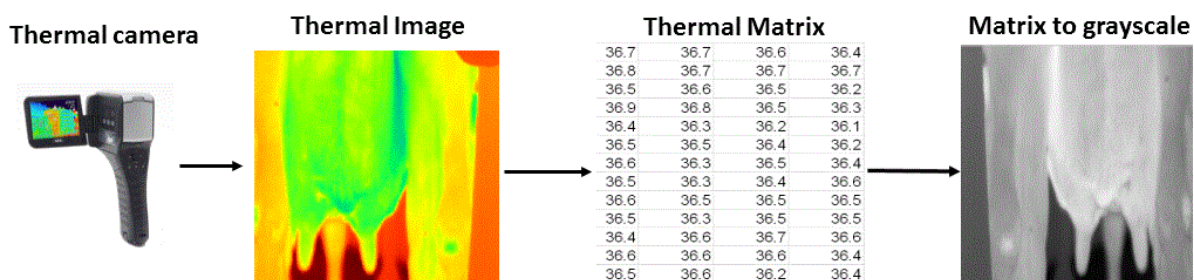


Figure 2 Temperature extraction procedure from different udder regions

RESULTS AND DISCUSSION

Reference cattle separation techniques

The average of daily milk productions for the studied dairy cows, which presumably were unhealthy with BM, are shown in Table 1.

According to this data, the milk production within a given period had declined smoothly. At the same time, an important conventional method in diagnosing BM and separating healthy and unhealthy cow is SCC per mL milk (Table 2). As shown in this Table, SCC had an increasing trend in milk samples, as unhealthy cows had SCC levels higher than 450000 per mL milk.

Another widely-used BM-pathogen detection technique from milk is CMT. Most of the studied milk samples had highly concentrated milk clots, which, according to CMT, they were positive for BM. According to range establish by Guccione (2013), all CMT reactions were scored in: 0 (negative), +/- (trace), 1 (weak positive), 2 (distinct positive), 3 (strong positive). The glands with distinct and strong positive were also determined as test references for thermal imaging (Table 3).

Comparison between conventional methods for BM detection

As the P-value from the results of Spearman's Rho test for testing the existence of the relationship between SCC and milk production was found to be less than 5%. We concluded that the confidence interval to reject the null hypothesis was at least 95%. Also, the results showed that there was an indirect correlation between milk's SCC value and milk production at 95% confidence (Table 4).

Thermal image processing results

Figure 3 shows the temperature dispersion of healthy and unhealthy tissues for all sixteen cows. The mean temperatures for healthy and unhealthy tissues were 35.70 °C and 35.26 °C. The temperature difference between these tissues (0.44 °C) was not significant. Table 5 presents the results for clustering extracted temperature pixels from both healthy and unhealthy tissues using the binary logistic regression model. Clustering the pixels into two categories of "healthy" and "unhealthy", we concluded that about 50% of pixels associated with unhealthy tissue were wrongly classified as "healthy".

Table 1 Avarage of daily milk production from studied cows

Cow-ID	Milk production (kg/day)	St. Dev.
1	32.71	4.60
2	31.51	5.56
3	32.22	4.77
4	32.13	3.56
5	31.34	1.78
6	31.64	4.85
7	30.25	2.01
8	29.62	3.16
9	28.26	4.13
10	26.37	5.18
11	25.64	3.66
12	22.44	4.52
13	21.42	2.36
14	20.54	4.67
15	15.25	4.11
16	10.56	5.01

Table 2 Avarage of monthly somatic cell count (SCC) factor in the milk of studied cows(per ml milk)

Cow-ID	SCC factor (*1000)	St. Dev.
1	464.13	20.21
2	504.06	31.88
3	624	21.75
4	860	26.56
5	988	19.78
6	1226	24.85
7	1380	14.01
8	1656	23.16
9	1666	14.13
10	1735	15.18
11	1851	19.66
12	2339	18.52
13	3579	20.36
14	4458	24.67
15	4614	30.11
16	5343	25.01

Table 3 Positive California mastitis test (CMT) cases and gland of sample origin

Sample No.	CMT test	Sample	Sample No.	CMT test	Sample
1	+2	Left-Rear	9	+2	Left-Front
2	+2	Right-Front	10	+1	Left-Front
3	+3	Right-Rear	11	+2	Right-Front
4	+3	Right-Rear	12	+3	Left-Front
5	+2	Right-Rear	13	+3	Right-Rear
6	+3	Left-Rear	14	+3	Right-Front
7	+2	Right-Rear	15	+3	Left-Rear
8	+2	Left-Rear	16	+2	Left-Rear

Table 4 Correlation between conventional methods for bovine mastitis (BM) detection

Variable	By variable	Spearman's Rho test	Significant > Rho
Somatic cell count (SCC)	milk production	-0.97	< 0.001
California mastitis test (CMT)	milk production	0.17	0.53
California mastitis test (CMT)	Somatic cell count (SCC)	0.27	0.31

This results in around 50% error in classification of unhealthy tissues. Similarly, the results of clustering showed just about 40% error in classifying healthy tissues from thermal images. The findings indicated that BM diagnosis accuracy using thermal maps was 57.3%.

Martins *et al.* (2013) reported mean thermographically-extracted udder surface temperatures for three types of healthy (36.06 °C), with clinical mastitis (35.89 °C) and with subclinical mastitis (36.3 °C) sheep based on the SCC factor.

Differences in these mean temperatures were not statistically significant ($P>0.05$). Results showed that sheep with subclinical mastitis had the highest temperature in both regions, which was due to increased blood flow caused by dilation of blood vessels. From the above-discussed findings, it can be hypothesized that blood flow can affect udder's surface temperature. By analyzing thermal maps, Polat *et al.* (2010) found that the temperature of an unhealthy udder tissue was 2.3 °C higher than that of a healthy one. Their results showed udder surface temperature had correlations with SCC ($r=0.73$) and with CMT ($r=0.86$). They suggested that the thermography can be used for detecting BM. The technique reliability, however, depends on the animal's characteristics, living conditions and above all environmental conditions, which should be further studied. Porcionato *et al.* (2009) studied the thermographic methodology for primary detection of subclinical mastitis. They reported that temperature differences between different udder regions were significant. That is, temperature at the upper region of udder was reported to be higher than the middle and lower regions. This indicates that the method can be used for diagnosing clinical mastitis, but not sub-clinical cases. Thermal image analysis used for clinical mastitis detection showed that the temperature difference between healthy and unhealthy tissues was between 1 and 1.5 °C. At the same time, temperatures in lateral images of udder tissue were approximately 0.6 °C higher than in medial ones. For practical implementation of this technique, it is necessary to mount the camera on the milking device or the automatic feeding system since udder is a sensitive region for diagnosing mastitis (Hovinen *et al.* 2008).

Colak *et al.* (2008) reported a high correlation ($r=0.92$) between skin thermography and CMT, therefore thermography can be used in diagnosing livestock for mastitis. However, there was no any correlation ($r=0.07$) found between CMT and body temperature. Therefore, body temperature cannot be used as key factor in detecting mastitis. Kennedy (2004) studied the feasibility of thermography. Their results indicated that infections on udder skin are the reason for the higher temperature of udder. They reported a 2-3 °C temperature difference between healthy and unhealthy tissues.

Various factors can reduce the accuracy of this method, including udder's touching the groin, hairs on the udder, non-uniform light irradiation and the presence of bulging blood vessels on skin. The region in which the natural lighting occurs seemed to be hotter than the shaded regions. Therefore, non-uniform lighting can cause some regions which are naturally cold, may seem to warm and vice versa in the thermal images. The region around the animal groin is usually warmer than udder. Therefore, the part of udder touching to groin appear warmer than it should be in the thermal images.

This is another source of error. Thermography detects the surface radiation. Hair blocks the heat radiated from the udder surface and affects the temperature reading by thermal camera. Bulging blood vessels are clearly a main part of error in reading temperature of udder surface. Other studies such as Hovinen *et al.* (2008); Colak *et al.* (2008); Martins *et al.* (2013) used thermography but never mentioned these sources of errors. Examples of such factors are shown in Figure 4.

Table 5 Clustering results extracted temperature pixels from both healthy and unhealthy tissues

Observed	Predicted		Percentage correct
	Healthy	Unhealthy	
Healthy	20860	13848	60.1
Unhealthy	15823	18869	54.4
Overall Percentage	-	-	57.3

Table 6 Mean comparison for the effect of sources of error on diagnosis accuracy using thermography

Item	Source	Type sum of squares	Df	Mean square (MS)	F	Sig
Non-uniform light irradiation	Group	9.45	1	9.452	28.64	.000
	Rep	395.72	2	197.862	599.67	.000
	Error	875.02	2652	0.330		
Udder's touching to groin	Group	494.18	1	494.18	2684.06	.000
	Rep	296.67	2	148.33	805.66	.000
	Error	368.97	2004	0.184		
Hair on udder surface	group	3951.93	1	3951.93	5475.33	.000
	Rep	6933.60	2	3466.80	4803.30	.000
	Error	1912.68	2650	0.722		
Presence or absence of skin lesions	group	2083.60	1	2083.60	2144.19	.000
	Rep	3249.92	2	1624.96	1672.21	.000
	Error	890.11	916	0.972		

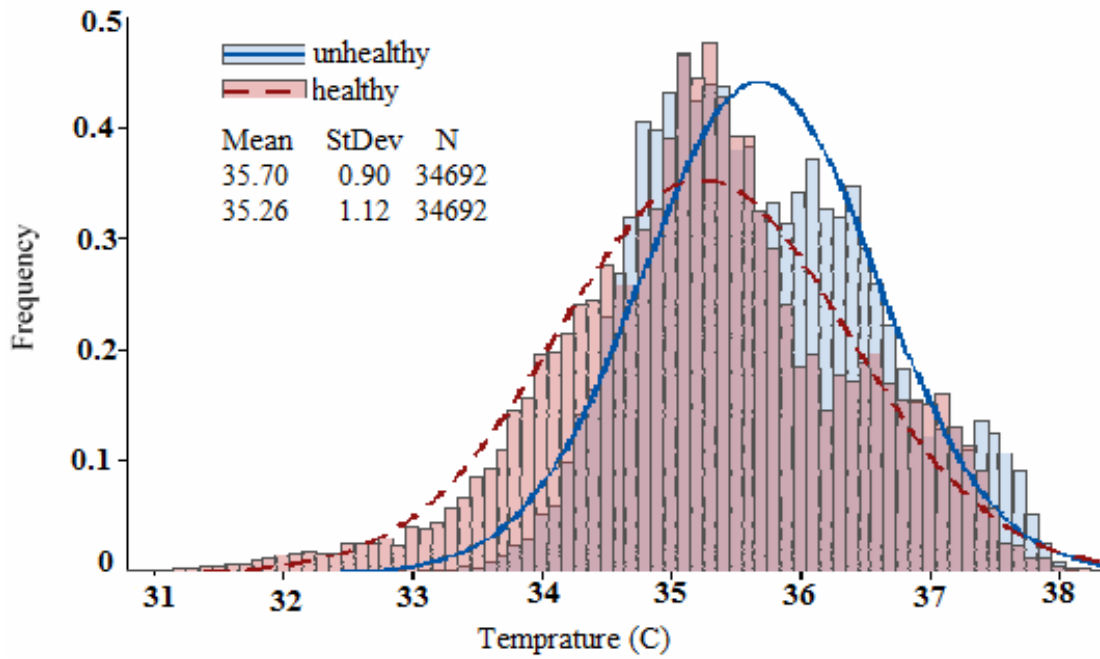
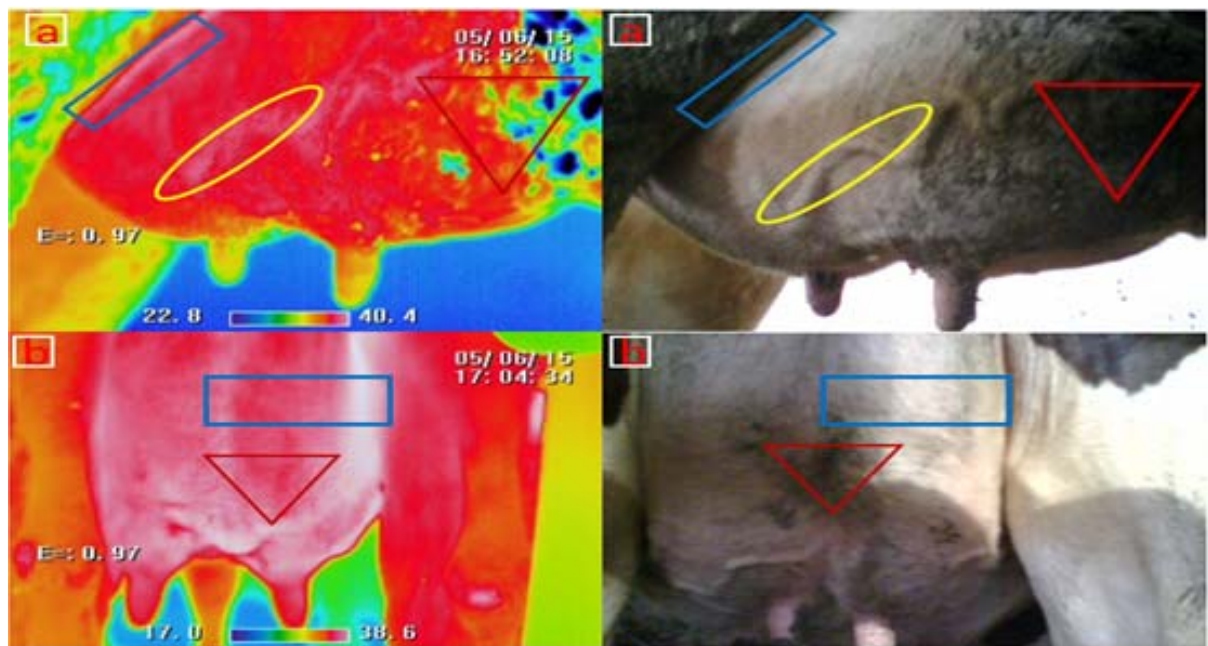


Figure 3 Dispersion distribution of temperature differences between healthy and unhealthy tissues



□: Udder's touching to groin; ▽: Hair on udder surface and ○: Presence of bulging blood vessels on skin

Figure 4 Error sources in thermal vs. non-thermal images

The results of the block design with three replications showed that the effects of all error parameters on diagnosis accuracy of thermal images were significant at the 95% probability level. For improved accuracy, it is suggested to minimize and control error parameters for future studies. As shown in Table 6, the effects of the four above-mentioned factors are studied.

It is shown that the effects of both treatment effect and block on temperature were significant at the 1% level.

CONCLUSION

Given the high importance of detecting mastitis and its effect on economic parameters as well as on health and wel-

fare of livestock, this study used the thermal map processing technique in this regard. The references for this method were SCC per mL milk, CMT results and milk production records. Thermographic BM detection results showed that thermography's detection accuracy was found to be 57.3%. Since very few studies have been done on thermographic detection of mastitis, it is suggested that future studies also control for parameters such as udder's touching to groin, hair on udder, reduced light effect and skin lesions in order to increase the precision of thermographic diagnosis of BM.

ACKNOWLEDGEMENT

We acknowledge the financial support provided by Ferdowsi University of Mashhad, Iran.

REFERENCES

- Alejandro M., Romero G., Sabater J.M. and Diaz J.R. (2014). Infrared thermography as a tool to determine teat tissue changes caused by machine milking in Murciano-Granadina goats. *Livest. Sci.* **160**, 178-185.
- Alsaad M., Syring C., Dietrich J., Doherr M.G., Gujan T. and Steiner A.A. (2014). A field trial of infrared thermography as a non-invasive diagnostic tool for early detection of digital dermatitis in dairy cows. *Vet. J.* **199**, 281-285.
- Ayareh D. and Mirzaei A.S. (2014). Effective factors on milk somatic cell count in clinical mastitis. *J. Vet. Res.* **69(2)**, 127-132.
- Barth K. (2000). Basic investigations to evaluate a highly sensitive infrared-thermograph-technique to detect udder inflammation in cows. *J. Milchwiss.* **55(11)**, 607-609.
- Bolourchi M., Hovareshti P. and Tabatabayi A.H. (2006). Comparison of the effects of local and systemic dry cow therapy for staphylococcal mastitis. *Prev. Vet. Med.* **25**, 63-67.
- Colak A., Polat B., Okumus Z., Kaya M., Yanmaz L.E. and Hayirli A. (2008). Early detection of mastitis using infrared thermography in dairy cows. *J. Dairy Sci.* **91**, 4244-4248.
- Cruz Júnior C.A., Lucci C.M., Peripolli V., Silva A.F., Menezes A.M., Morais S.R.L., Araújo M.S., Ribeiro L.M.C.S., Mattos R.C. and McManus C. (2015). Effects of testicle insulation on seminal traits in rams: preliminary study. *Small Rumin. Res.* **130**, 157-165.
- Davis J.G., Jones V.E. and Ward S.J. (1943). Rapid electrical methods for the measurements of souring and mastitis milk. Pp. 43-46 in Proc. Soc. Agric. Bact. Leeds, United Kingdom.
- Doosti-Irani O., Golzarian M.R., Aghkhani M.H., Sadrnia H. and Doosti-Irani M. (2016). Development of multiple regression model to estimate the apple's bruise depth using thermal maps. *Posth. Biol. Technol.* **116**, 75-79.
- Ferrero F.J., Valledor M. and Campo J.C. (2014). Screening method for early detection of mastitis in cows. *Measurement.* **47**, 855-860.
- Ghasemzadeh-Nava H. and Bokaie S. (2011). Evaluation of MAS-D-TEC set for detection of subclinical mastitis in goats. *Iranian Vet. J.* **7(3)**, 27-34.
- Ghorbanpour M., Seifiabad-Shapouri M.R., Motamedi H., Jamshidianand M. and Gouraninejad S. (2007). Comparison of microbial culture methods, PCR and California mastitis test for the detection of staphylococcal and streptococcal subclinical staphylococcal mastitis. *Iranian Vet. J.* **3(1)**, 11-17.
- Guccione J. (2013). Clinical and diagnostically aspects in dairy Mediterranean buffalo mastitis. Ph D. Thesis. University of Napoli Federico, Napoli, Italy.
- Heringstad B., Klemetsdal G. and Ruane J. (2000). Selection for mastitis resistance in dairy cattle: a review with focus on the situation in the Nordic countries. *Livest. Prod. Sci.* **4**, 95-106.
- Hovinen M., Siivonen J., Taponen S., Hänninen L., Pastell M., Aisla A.M. and Pyörälä S. (2008). Detection of clinical mastitis with the help of a thermal camera. *J. Dairy Sci.* **91**, 4592-4598.
- Kamphuis C., Mollenhorst H., Feelders A., Pietersma D. and Hogeveen H. (2010). Decision-tree induction to detect clinical mastitis with automatic milking. *Comput. Elect. Agric.* **70(1)**, 60-68.
- Kennedy A. (2004). Mastitis detection using infrared thermography. *Western Dairy Digest.* **5(4)**, 15.
- Martins R.F.S., do Prado Paim T., de Abreu Cardoso C., Stéfano Lima Dallago B., de Melo C.B., Louvandini H. and McManus C. (2013). Mastitis detection in sheep by infrared thermography. *Res. Vet. Sci.* **94**, 722-724.
- McManus C., Tanure C.B., Peripolli V., Seixas L., Fischer L., Gabbi A.M., Silvio R.O., Menegassi S.R., Stumpf M.T., Kolling G.J. and Dias Eduardo Costa Jr J.B.G. (2016). Infrared thermography in animal production: An overview. *Comput. Elect. Agric.* **123**, 10-16.
- Menegassi S.R.O., Barcellos J.O.J., Dias E.A., Koetz C., Pereira G.R., Peripolli V., Mcmanu C., Canozzi M.E.A. and Lopes F.G. (2015). Scrotal infrared digital thermography as a predictor of seasonal effects on sperm traits in Braford bulls. *Int. J. Biometeorol.* **59(3)**, 357-364.
- Najafi M. and Mortazavi S.A. (2009). Effect of somatic cell count on milk composition in Khorasan Razavi province. *J. Food Sci. Technol.* **6(2)**, 24-32.
- Nikkhah A., Plaizier J.C., Einarson M.S., Berry R.J., Scott S.L. and Kennedy A.D. (2005). Infrared thermography and visual examination of hooves of dairy cows in two stages of lactation. *J. Dairy Sci.* **88**, 2749-53.
- Norberg E. (2005). Electrical conductivity of milk as a phenotypic and genetic indicator of bovine mastitis: a review. *Livest. Prod. Sci.* **96**, 129-139.
- Paim T.P., Borges B.O. and Lima P.M.T. (2012). Relation between thermographic temperatures of lambs and thermal comfort indices. *Int. J. Appl. Anim. Sci.* **1(4)**, 108-115.
- Poikalainen V., Veermäe J.P. and Kokin E. (2012). Infrared temperature patterns of cow's body as an indicator for health control at precision cattle farming. *Agric. Res. Biol. Engin.* **1**, 187-194.
- Polat B., Colak B., Cengiz M., Yanmaz L.E., Bastan A., Kaya S. and Hayirli A. (2010). Sensitivity and specificity of infrared thermography in detection of subclinical mastitis in dairy cows. *J. Dairy Sci.* **93(8)**, 3525-3532.
- Porcionato M.A.F., Canata T.F., Deoliviera C.L. and Dossattos M.V. (2009). Udder thermography of gyr cows for subclinical

- mastitis detection. *Biol. Engin. Camp.* **3(3)**, 251-257.
- Quinn P.J., Carter M.E., Markey B. and Carter G.R. (1994). *Clinical Veterinary Microbiology*. Wolfe Publishing, London, United Kingdom.
- Schaefer A.L., Cook N.J., Bench C., Chabot J.B., Colyn J., Liu T., Okine E.K., Stewart M. and Webster J.R. (2012). The non-invasive and automated detection of bovine respiratory disease onset in receiver calves using infrared thermography. *Res. Vet. Sci.* **93**, 928-935.
- Simões V.G., Lyazrhi F., Picard-Hagen N., Gayraud V., Martineau G.P. and Waret- Szkuta A. (2014). Variations in the vulvar temperature of sows during proestrus and estrus as determined by infrared thermography and its relation to ovulation. *Theriogenology*. **82(8)**, 1080-1085.
- Stelletta C., Giancesella M., Vencato J., Fiore E. and Morgante M. (2012). Thermographic applications in veterinary medicine. Pp 117-140 in *Infrared Thermography*. R.V. Prakash, Ed. In Tech Open Access Publisher, China.
- Viguier C., Arora S., Gilmartin N., Welbeck K. and O'Kennedy R. (2009). Mastitis detection: current trends and future perspectives. *Trends Biotechnol.* **27**, 486-493.
- Weschenfelder A.V., Saucier L., Maldague X., Rocha L.M., Schaefer A.L. and Faucitano L. (2013). Use of infrared ocular thermography to assess physiological conditions of pigs prior to slaughter and predict pork quality variation. *Meat Sci.* **95**, 616-620.
- Windig J.J., Calus M.P.L. and Veerkamp R.F. (2005). Influence of herd environment on health and fertility and their relationship with milk production. *J. Dairy Sci.* **88(1)**, 335-347.
-